

CHANGES IN THE STRUCTURE OF RABBIT'S TESTICLES UNDER DIFFERENT WAYS OF HEATING

V. Botsman, N. Cherny, V. Simonenko, I. Shetinski, A. Zakhar'ev

*Kharkov State Zooveterinary Academy,
Malaya Danilovka, Dergachovsky district, Kharkov region, 62341, Ukraine*

V. Ivanov, A. Silin

*Institute of Radiophysics and Electronics, National Academy of Sciences of Ukraine,
12, Akademika Proskury st., Kharkov, 61085, Ukraine*

Key words: electromagnetic radiation, infrared, microwave, testicle, necrosis, hyperaemia.

Introduction

Microwave and infrared (IR) electromagnetic radiation (EMR) is used the most widely in curative practice. Positive results in treatment of many diseases including oncological ones allow telling about the high effectiveness of these methods (S.B. Filed, Devyatkov). Character of many biological processes depends on intensity and spectral composition of radiation and is used for purposeful influence upon the animals and man (Chizhevsky).

Material and methods

For investigations in determination of influence upon testicles of EMR of microwave (at frequency of 2.45 GHz) and IR-ranges (wave length about 3 μm) were selected five-month old rabbits.

A generator was continuously radiating 20 W. Applicator was brought to the contact of scrotum cutis. IR radiation source is a lamp of IRT-220-250 type, placed in the focus of parabolic reflector at the 0.3 m distance from testicles. The temperature in the testicles centre was controlled by an electronic thermometer (thermocouple at the end of injection needle).

Testicles irradiation was continued before the temperature has been raised to 9.5°C (at frequency of 2.45 GHz – 1 minute, IR – 6 minutes). 48 hours later the rabbits were gelded in closed way. Testicles and appendices fragments were fixed, flooded and coloured by hematoxilinum and eozinum after adopted methods (Merculov).

Results

During the running of histological microscopic section analysis it was determined that the injuries of testicles structure took place both with using of EMR in microwave (2.45 GHz) and IR ranges, but character of injuries and their distribution in testicle size were considerably

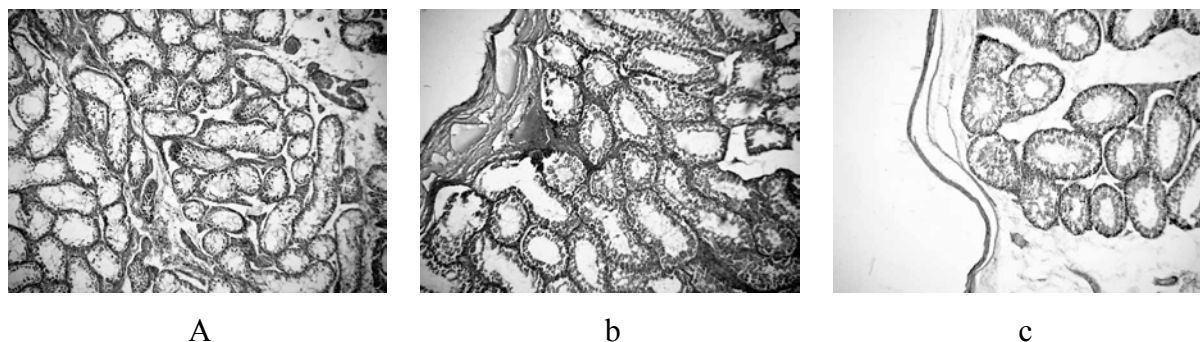
different. Injuries under influence of microwave radiation were relatively bad visible on the superficial layers (on the applicator location side) and they were more visible in the deep layers. Injuries heaviness under influence of IR radiation was maximum at the surface (about one tenth of testicle thickness from the side of source location) and was more less in the direction to the organ centre. Layer thickness where the injuries were visible didn't exceed.

After influence of microwave radiation in the testicle depth the large necrotic dissociation fields of all testicle components are visible: connective – tissue framework, vessels, twisting canals (Fig. 1a). Basal membranes and cells of spermgenic epithelium locating on them both mature and cambial are dissociated. Oxiphilic masses of conglomerates mixed with hydrants are observed at the place of these dissociations. They have gas bubbles.

Near the testicle membrane are observed too heavy pathologies, but they aren't so heavy as in the depth (Fig. 1b). Compactisation of twisting canals is disturbed. There are too large cavities between them which move canals from each other. Many basal membranes of these canals break off. All canal epithelium of this testicle zone including spermgenic is perished. Only basal membranes from twisting testicle canals are alive. They don't change and they are bounds of former canals. The vessels in this zone are overfilled and enlarged. The mature sperms in canal aperture of appendix are absent completely.

In the testicle centre after influence of IR radiation the usual texture is remained. Hyperaemia and hyperhilemia are developed near the superficial layers. Arterial and venous vessels are increased. Connective-tissue framework of testicle is remained, but the big fibres are visible swelled in separate places.

The largest injuries are observed in the testicle membranes. They stop to be continuous and dissociate into fibres. Serous pathological transsudat is accumulated, blood and lymphatic vessels are increased greatly and overfilled by blood and lymph accordingly (Fig. 1c). Some of dissociated fibres are coagulated very heavily and are caked with formation of homogenous mass, but the external form of fibres is remained. Mass destruction of mature cellular elements of twisting canals walls is observed. They are undergone the coagulated necroses, decreased in sizes and homogenisired and converted into small roundednesses. The volume desquamation takes place too. Cellular elements tear away from basal membrane into the aperture and coagulate there. In the aperture of many twisting canals appear necroprotein coagulants. But cellular generations of deep layers – spermatogoniae are served in the most of twisting canals.



a - deep layers (microwave), ob. 10
b - superficial layers (microwave), ob. 20
c - superficial layers (IR), ob.

Figure 1 The testicle general hystologic structure

Leiding's cell are perished (they are undergone coagulative necrosis). The cells of the twisting canal walls are perished too under influence of both ranges of radiation. But after influence of microwave radiation they are perished to a considerable extent more.

Discussion

Changes of testicle structure in rabbits are connected with temperature influence according to our point of view. Injuries degree depends on the absolute meaning and the speed of temperature increasing. Under influence of EMR the tissue temperature increases, it being know that at the surface, from the side of electro-magnetic wave drop, the temperature is higher. Microwave radiation penetrates into testicle more deeper than IR radiation, so the temperature in the centre increased both as a result of direct heating by electro-magnetic field and owing to heat transmission from heated to more higher temperature of superficial layers. It has secured higher speed of temperature increasing.

The whole energy of IR range radiation has been absorbed in the upper layer of testicle (the depth of radiation penetration is 1-3 mm order) and the heating of central part has occurred only by means of heat transmission and it hasn't had practically any visible changes. According to our point of view such heating conditions and term of influence (6 times more) explain the character of injuries – some of fibers are even caked.

Important gradients of temperature within the cellular structures of testicle under influence of microwave radiation could appear in that case when their dielectric permeability differs considerably.

Conclusion

Investigation results have been shown a high effectiveness of application of microwave radiation for function oppression of testicle in rabbits. It's necessary to obtain more specific information about the meaning of dielectric permeability of some elements of testicle structure and response reactions of animal body on render assistance for the practical realization of this method.

References.

1. *Chizhevski A.L. Ground echoed solar storms. 2-nd Ed., Moscow: Mysl, 1976. - 386 p. (in Russian).*
2. *S.B.Filed. Hypothermia in the treatment of cancer//Physics in medicine and biology. -1987. -Vol. 32, P. 789-811.*
3. *Devyatkov A.D., Golant M.B., Betski O.V. Millimetre waves and their role in vital activity. - M.: Radio and communication, 1991. – 169 p. (in Russian).*
4. *Merkulov G.A. Treatise on histologic technology. 5-th ed. Meditsina Press. Leningrad branch. 1969. 423 p. (in Russian).*